

The Effect of Crude oil on Gastro-Intestinal Motility and Histology of Ileum of Female Wistar Rats

Naiho Alexander Obidike

Department of Physiology, Delta State University Abraka, Delta State. Nigeria.

(Received: 22 December 2011; accepted: 21 January 2012)

Crude oil is a common pollutant in Nigeria, it has been estimated that an average of 11-54mg/L of the oil is dissolved in our coastal waters. This work examined the effect of crude oil on gastro-intestinal motility and histology of the ileum. 18 female wistar rats were used for the experiment and divided into three; control group A, experimental group B and experimental group C. The group A was administered with Rat Chow and Water while, the group B and group C received 10mg/kg and 15mg/kg mixture of crude oil and water respectively for a period of 21 days. The animals were weighed and sacrificed after an overnight fast and oral ingestion of activated charcoal meal. It was observed that there was a significant reduction in weight gain of the experimental groups compared to that of the control group. Group B (10mg/kg) and group C rats showed increased in intestinal motility when compared to control group but between the two there was no significant difference. Histological sections of the ileum of experimental rats showed different structural distortions. We therefore conclude that oral ingestion of crude oil is capable of reducing gastrointestinal retention time and hinder absorption of nutrients which may be related to its ability to cause several structural distortion of the rats intestine.

Key words: Ileum, Histology, Motility and Crude oil.

The impact of crude oil spillage on the ecosystem of the Niger delta region of Nigeria is enormous. Large area of mangrove forests (an estimated 5-10% of Nigeria mangrove ecosystems) have been wiped out by oil as it contaminates soil and groundwater. Offshore spills, which are even greater in scale, contaminate coastal environments, drinking water and wiped out aquatic life and thus reduce local fishing activities (Baird, 2010).

Despite the adverse effects of crude oil spills on human ecosystem, crude oil is employed traditionally for medicinal purposes in rural areas of the Niger delta of Nigeria. It is believed to be useful in the local treatment of snake bite (Dede *et al*, 2002), and an antidote to various poisoning and cure for various intestinal disturbances (Eyong *et al*, 2004). We therefore set out to determine the effect of ingestion of crude oil contaminated water on gastrointestinal motility and the anatomy of the ileum in wistar rats, with a view to determine if there are any adverse effects associated with oral ingestion of crude oil.

MATERIALS AND METHODS

Bonny light crude oil (BLCO) was procured from Nigerian National Petroleum

* To whom all correspondence should be addressed.

Corporation (NNPC) and activated charcoal was obtained from a local pharmaceutical company.

Eighteen albino wistar rats were purchased from the animal house of the faculty of basic medical sciences, Ambrose Ali University, Ekpoma. The rats were housed in the animal house of the faculty of basic Medical science, Delta State University, Abraka, with 12 hours light and 12 hours dark cycle to acclimatize to housing conditions for two weeks prior to experiment.

Table 1. Effects of crude oil on Gastrointestinal motility: Showing length of small intestine (cm), distance of small intestine moved (cm) and percentage of distance moved (%).

	Length of small intestine (cm)	Distance of small intestine moved (cm)	Percentage of distance moved (%)
Control group A	85.8 \pm 2.59	75.3 \pm 4.8	82.5 \pm 1.5
Group B (Exp 1)	87.4 \pm 5.96	76.4 \pm 4.2	88.2 \pm 3.8 ^{cd}
Group C (Exp2)	99.3 \pm 2.8	88.2 \pm 3.7	88.7 \pm 3.0 ^{cd}

Values are expressed in mean \pm standard error of mean (SEM), n=6

^cP<0.05 was considered significant when compared with control group

^dP>0.05 was considered insignificant when Exp 1 was compared with Exp 2.

Table 2. Effects of crude oil on rats' weight (g).

	Initial Weight (g)	Final Weight (g)
Control group A	188.3 \pm 4.0	216.7 \pm 6.1
Group B (Exp 1)	191.7 \pm 5.43	173.3 \pm 5.1 ^{ca}
Group C (Exp2)	223.3 \pm 8.0	203.3 \pm 9.9 ^{ca}

Values are expressed in mean \pm standard error of mean (SEM), n=6

^aP<0.05 was considered significant when compared with control group

^cP<0.05 was considered significant when group B was compared with group C.

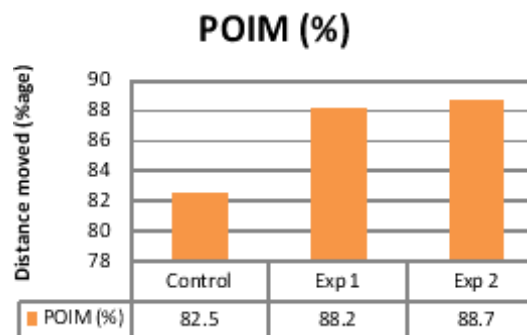


Fig. 1. Effects of crude oil on percentage (%) distance of intestine moved.

POIM=Percentage distance of intestine moved.

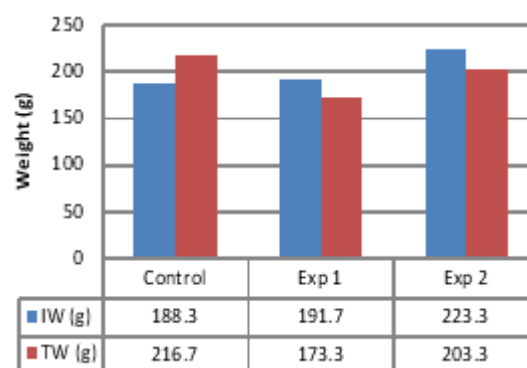


Fig 2: Effects of crude oil on body weight of rats before and after administration.

IW=Initial weight

TW=Terminal weight

EXPERIMENTAL

The rats were divided into three groups of six rats each. The control group (group A) received rat chow and tap water ad libitum. The experimental animals in group B were exposed to bonny light crude oil in their drinking water at a dose of 10mg/kg body weight (low dose) while the experimental animals in group C were exposed to crude oil in their drinking water at a dose of 15mg/kg body weight (high dose). Both experimental groups received rat chow ad libitum. Administration lasted for 21 days before experiment and harvest of tissues.

The animals in the control group and experimental groups were weighed to determine

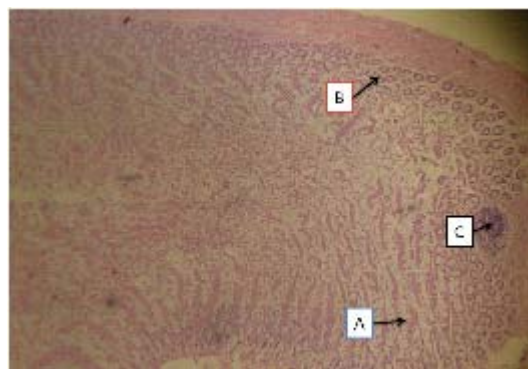


Fig. 3. Ileum of control rats [H&E x10] showing normal mucosal villi (A), normal Brunner's glands (B) and a normal lymphoid in the lamina propria (C).

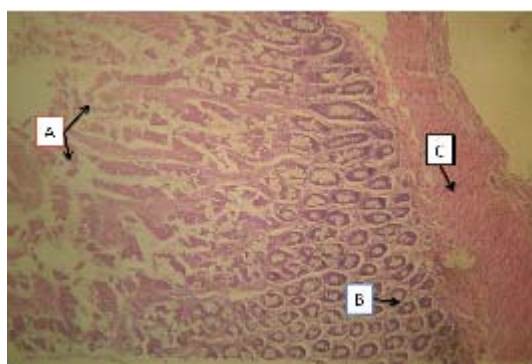


Fig. 4. Ileum of rat treated with Crude oil (10mg/kg) [H&E x10] showing severe degeneration of mucosal villi (A), mild degeneration of the Brunner's glands (B), without involving the muscularis propria (C).

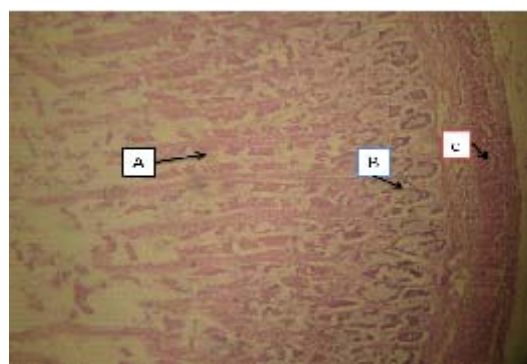


Fig. 5. Ileum of rat treated with crude oil 10mg/kg [H&E x10], showing severe degeneration (atrophy) of mucosal villi (A), moderate degeneration of the Brunner's glands (B) and without involving the muscularis propria (C).

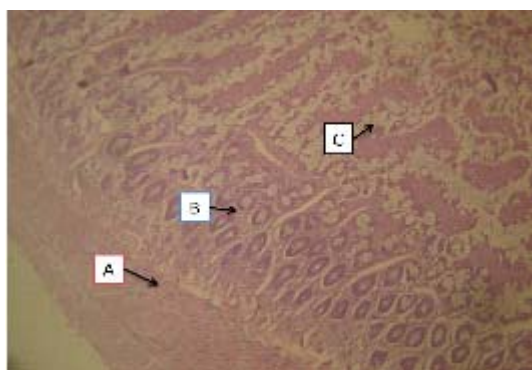


Fig. 6. Ileum of rat treated with crude oil 15mg/kg [H&E x10] showing severe degeneration (atrophy) of mucosal villi (A), without involving the Brunner's glands (B) and the muscularis propria (C).

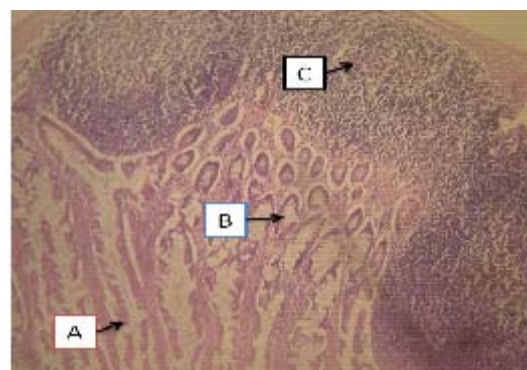


Fig. 7. Ileum of rat treated with crude oil 15mg/kg [H&E x10] showing severe degeneration (atrophy) of mucosal villi (A), moderate degeneration of the Brunner's glands (B) and activated peyer's patches or lymphoid aggregates (C).

their terminal weights. Each animal was orally administered with 1.3ml of charcoal meal (5g activated charcoal mixed in 100ml of distilled water). After 30 minutes, each animal was sacrificed, the gastrointestinal tract was extracted and the small intestine was stretched out and closely observed, the length of the small intestine of each animal was measured using a meter rule and the distance moved by the charcoal meal in the small intestine of each animal was measured and expressed as percentage of distance moved. At the end of the gastrointestinal motility test, a section of ileum of control and experimental animals was harvested. The harvested tissues were immediately preserved in 10% formalin in separate universal bottles bearing appropriate tags. The tissues were taken for histological analysis. Student's *t* test was used for data analysis.

RESULTS

The results showed that crude oil ingestion caused an increase in intestinal motility and reduction in weight of experimental rats.

DISCUSSION

Experimental rats treated with 10mg/kg and 15mg/kg of diesel had a significant effect on gastrointestinal motility when compared to the control group ($P < 0.05$; Table 1). This result confirms that crude oil reduces gastrointestinal retention time. It correlates with results obtained in the study carried out on river otters exposed to crude oil at doses of 5mg/kg and 50mg/kg by Ormseth and Ben-David (2000) whose study results indicated that ingested crude increased motility in the river otters exposed to crude oil. There was no observed significant difference in the effect of the high dose (15 mg/kg) experimental group C (on gastrointestinal motility when compared with the effect of the low dose (10 mg/kg) experimental group B ($P > 0.05$; Table 1). This observation contradicts the results from research conducted by Ormseth and Ben-David, (2000) on river otters exposed to crude oil, in which the animals treated with high dose crude oil (50 mg/kg), showed a significantly higher gut motility rate when compared with the low dose crude oil (5mg/kg) treated animals. This may be attributable to the

closeness between doses 10mg/kg and 15mg/kg used in this study as against 5mg/kg and 50mg/kg used in the research study by Ormseth and Ben-David (2000).

There was observed gross weight gain in the control group when the initial and terminal weights of experimental group B and experimental group C were compared with the control group ($P < 0.05$, Table 2). This observation of reduction in weight in experimental animals exposed to crude oil collaborates with results obtained in the study carried out by Ormseth and Ben-David (2000). The indication of weight loss in the results in Table 2 is supported by the observation that retention time relates with nutrient uptake in the gut with the quality of diet in consideration, hence, reduced gut retention time is associated with decreased digestibility and absorption resulting in malnutrition which results in weight loss as reported by Hilton *et al*, (1998).

Photomicrograph of control rats (Fig. 3.) shows a normal small intestine (ileum) with the mucosal villi, Brunner's glands and lymphoid nodules indicated to appear normal. The slides of experimental animals treated with crude oil (10mg/kg) showed slight alterations in histological structures (Fig. 4. and 5.) showing severe degeneration of the Brunner's gland, atrophy of the mucosal villi, with the muscularis propria remaining normal.

The slides of experimental animals treated with crude oil (15mg/kg) showed gross alterations in histological structure (Fig. 6. and 7.) showing severe degeneration (atrophy) of mucosal villi, moderate degeneration of the Brunner's glands and activated Peyer's patches or lymphoid aggregates. Result from this study indicates that crude oil impacts negatively on the histology of the ileum resulting in destruction of the lining of the ileum and other vital structures, the severity of which increases with concentration.

CONCLUSION

This research study confirms that crude oil impacts on gastrointestinal motility to reduce gut retention time, affecting digestibility and absorption of nutrients negatively, resulting in malnutrition as indicated by gross weight loss in experimental animals. This study also indicates that

the effect of crude oil on the histology of the ileum is adverse, the severity of which increases with increasing concentration, resulting in alterations in vital histological structures of the ileum. All of these effects aggregate to confirm the association between potential health hazards and ingested crude oil.

REFERENCES

1. Baird, J. "Oil's Shame in Africa". Newsweek. (2010).
2. Dede, E.B. Igboh N.M and Ayalogu O.A. Chronic Toxicity Study of the effect of Crude Petroleum (Bonny Light), Kerosene and gasoline on Rats using Haematological Parameters, *J. App. Sci. Evron. Mgt.* **6**(1): 60-63 (2002).
3. Eyong, E.U. Haematotoxic effects following ingestion of Nigerian Crude Oil Polluted Shell fish by rats, *Nigeria Journal of Physiological Science.* **19**(1-2): 1-6 (2005).
4. Hilton G.M, Houston D.C, Furness R.W. Which component of diet quality affects retention time of digesta in sea birds. *Functional Ecology*, **12**: 929-939 (1998).
5. Ormseth O.A, M. Ben-David. Ingestion of Crude Oil: effects on digesta retention times and nutrient uptake in captive river otters, **170**: 419-428 (2000).